

Anterior uveitis after treatment of age-related macular degeneration with ranibizumab and bevacizumab: uncommon complication

Nadyr Damasceno¹
Soraya Horowitz²
Eduardo Damasceno³

^{1,2}Ophthalmology Department, Hospital Naval Marcilio Dias, Rio de Janeiro, Brazil; ³Department of Ophthalmology, Universidade Federal Fluminense, Niteroi, Brazil

Abstract: The authors describe one case of anterior uveitis after treatment of age-related macular degeneration with both antiangiogenic drugs: ranibizumab and bevacizumab. The case is described as a complication of ranibizumab and bevacizumab due to an inflammatory process. Several reasons are suggested to explain this possibility, and the authors conclude that the main cause remains unknown.

Keywords: antiangiogenic agent, complications, ocular inflammatory process, ranibizumab, bevacizumab, anterior uveitis

Case report

Age-related macular degeneration (ARMD) is the leading cause of blindness in developed countries.¹ Since 2005, the advent of antivascular endothelial growth factor (anti-VEGF) drugs for the treatment of the neovascular ARMD has changed the management of this disease. The prognosis of this disease has improved, but each intravitreal injection increases the risk of complications. Although very uncommon, an inflammatory process is one of these complications.^{1,2} This report describes a case of anterior uveitis following treatment with ranibizumab on the left eye and after 2 months with the same inflammatory process with bevacizumab on the right eye.

A 78-year-old white woman reported ocular hyperemia of the left eye for 3 days after intravitreal injection of ranibizumab. She had a history of five injections of ranibizumab due to treatment of neovascular AMD during 1 year in the same eye. All intravitreal injections were made after informed consent and performed in the operating room with topical anesthesia and aseptic techniques. She had had cataract surgery 3 years previously, before starting ranibizumab treatment. There was an anterior chamber intraocular lens in that eye. Examination of both eyes revealed visual acuity of 20/120 on the Early Treatment of Diabetic Retinopathy chart with correction. Biomicroscopy of the anterior segment of the left eye revealed cells (+2/+4), keratic precipitates (+2/+4), and conjunctival hyperemia without discharge (Figures 1 and 2). There was no complaining about ocular pain. Intraocular pressure was 12 mmHg in both eyes. Color retinography and fluorescein angiography showed macular disciform scars on both eyes (Figure 3). Optical coherence tomography images of the left eye revealed involution of choroidal neovascularization from the beginning to the end of anti-VEGF drugs treatment (Figures 4 and 5).

Immunological studies for toxoplasmosis, cytomegalovirus, herpes, rubella, HIV and syphilis tests were all negative. Blood and rheumatological tests, purified

Correspondence: Eduardo Damasceno
Department of Ophthalmology,
Universidade Federal Fluminense, 9 Rua
Miguel de Frias, Icaraí, Niterói, Rio de
Janeiro, Brazil
Email e_damasceno@yahoo.com

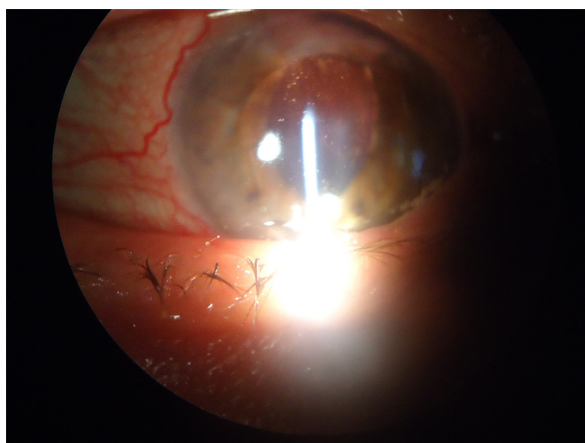


Figure 1 Anterior segment details – conjunctival hyperemia and anterior chamber intraocular lens (LEFT EYE).

Note: Anterior uveitis after ranibizumab.

protein derivative, and chest radiograph were negative. As part of the investigative process, an aqueous humor culture was taken, after anterior chamber access to take samples. Fungal and bacteriological searches were made on this material. The final results were negative.

The patient's anterior uveitis was treated with cycloplegics and topical corticoids. No antibiotic therapy was required. There was successful control of the ocular inflammation after 1 month. Ranibizumab therapy was discontinued.

Three months after this inflammatory complication, Avastin (Genentech, South San Francisco, CA) therapy (bevacizumab 0.1 mL, 100 mg/4 mL) was chosen for the treatment of wet ARMD in the right eye. After this therapy

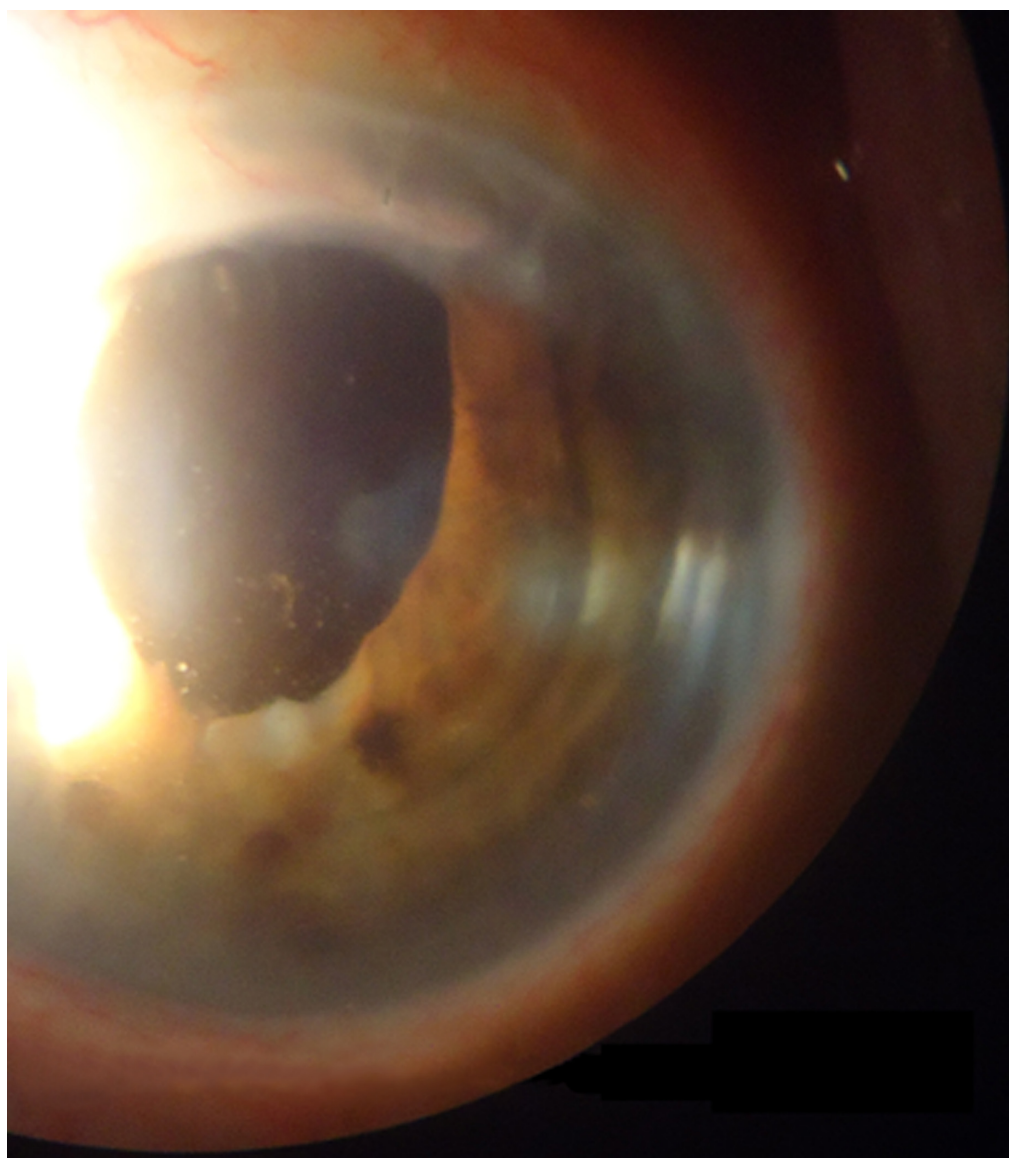


Figure 2 Anterior chamber lens details (LEFT EYE).

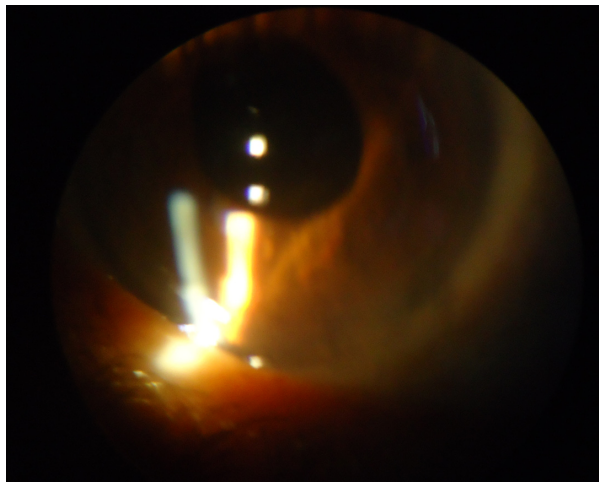


Figure 3 Right eye – mild anterior uveitis with cells.
Note: Anterior uveitis after bevacizumab treatment.

was begun, with the second intravitreal injection, the same anterior uveitis with cells in aqueous humor, keratic precipitates, and mild conjunctival hyperemia developed in the right eye. In Brazil, Avastin comes in single-use 0.1-mL microampoules, and so the same aqueous humor culture after anterior chamber samples was taken again. As in the left eye, the final results were negative in this right eye. Once more, the patient's anterior uveitis was treated with cycloplegics and topical corticoids. No antibiotic therapy was required. There was successful control of the ocular inflammation after 1 month. In the same way, bevacizumab therapy was discontinued. Different to the left eye, the right eye had a posterior intraocular lens with the posterior capsule anatomically perfect, due to cataract surgery performed 5 years previously.

STRATUS OCT
 Median smoothing report – 5.0.1 (0376)



Scan type: Macular thickness map OS

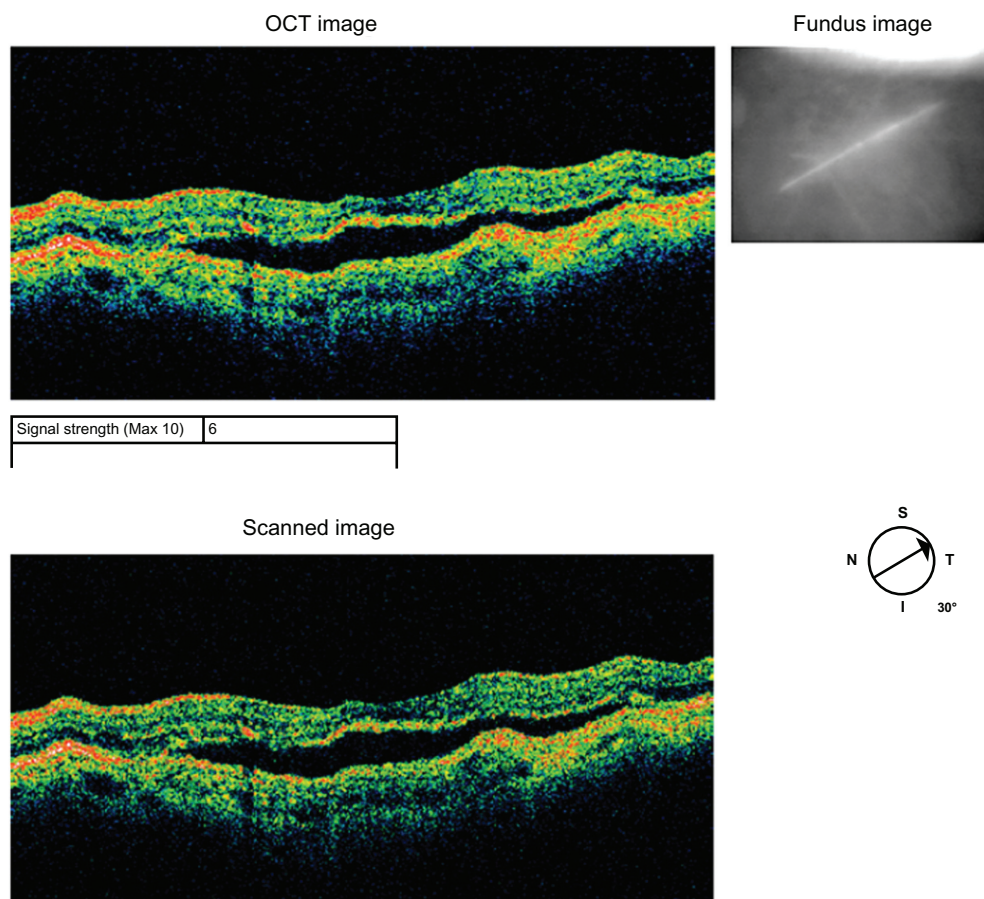


Figure 4 OCT image – active exudative ARMD.
Note: In the beginning of ranibizumab treatment.

Abbreviations: ARMD, age-related macular degeneration; OCT, optical coherence tomography.

STRATUS OCT
Median smoothing report – 5.0.1 (0376)


Scan type: Macular thickness map OS

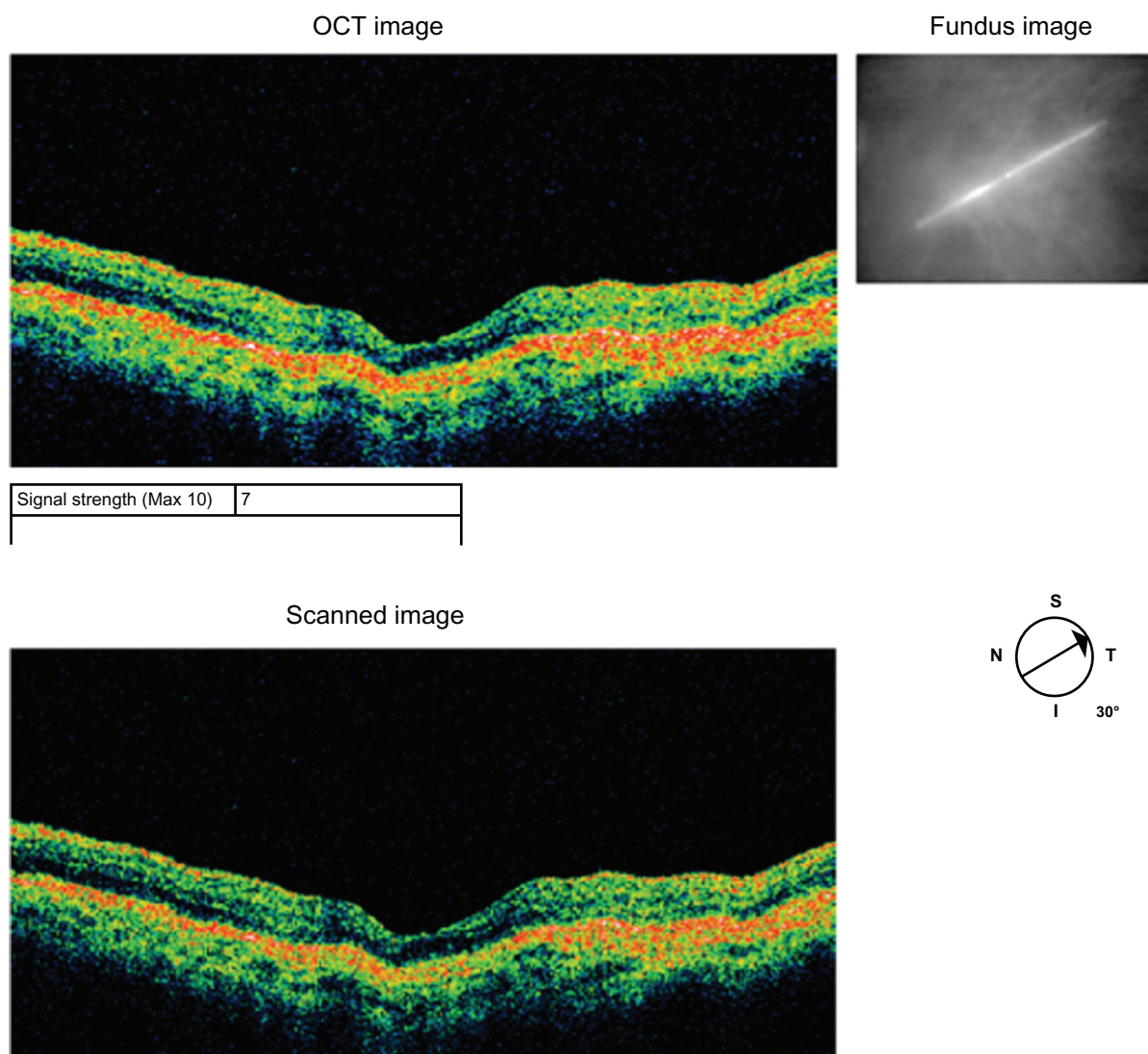


Figure 5 OCT image – inactive ARMD.

Note: In the end of treatment.

Abbreviations: ARMD, age-related macular degeneration; OCT, optical coherence tomography.

Discussion

Ranibizumab is a humanized antigen-binding fragment derived from a murine monoclonal anti-vascular endothelial growth factor (VEGF)-A antibody.³ VEGF plays a role in angiogenesis and in increasing vascular permeability. Complications following inflammatory processes are seldom reported, even considering specific antibodies as protein injected inside the eye. Bevacizumab is a possible origin of the immunogenic response due

its molecules being significant larger than ranibizumab and spending more time into the vitreous cavity. A hypothesis to explain inflammatory process based on toxic anterior segment syndrome is also considered as one of probable etiology; the expression of VEGF is also linked to that of major cytokines in the inflammatory cascade.⁴ Another hypothesis is the compensatory elevations of angiogenics and inflammatory factors following VEGF inhibition, which has also been reported.⁴

It is possible that with repeated intravitreal injections, there is an increased risk of an inflammatory response because of an immune-mediated response to the ranibizumab by a recombinant humanized monoclonal antibody that is directed against all isoforms of VEGF.

Sterile endophthalmitis was ruled out because the patient had only an anterior chamber reaction without vitreous inflammation.^{4,5} Nevertheless, the kind of inflammation described in these case reports could be consistent with toxic anterior segment syndrome as a result of intravitreal injection of ranibizumab or bevacizumab in an eye with anterior chamber intraocular lens implantation without the protective effect of a posterior capsule lens. Cross-reaction to inflammatory processes between the two anti-VEGF drugs was not reported in the literature.

In summary, a case of ranibizumab and bevacizumab therapy complication related to an inflammatory process after treatment of ARMD was described. The reasons for the complication remain unknown.

Disclosure

The authors report no conflicts of interest in this work.

References

1. Day S, Acquah K, Mruthyunjaya P, Grossman DS, Lee PP, Sloan FA. Ocular complications after anti-vascular endothelial growth factor therapy in Medicare patients with age-related macular degeneration. *Am J Ophthalmol*. 2011;152(2):266–272.
2. Fung AE, Rosenfeld PJ, Reichel E. The International Intravitreal Bevacizumab Safety Survey: using the internet to assess drug safety worldwide. *Br J Ophthalmol*. 2006;90(11):1344–1349.
3. Gulati N, Forooghian F, Lieberman R, Jabs AD. Vascular endothelial growth factor inhibition in uveitis: a systemic review. *Br J Ophthalmol*. 2011;95:162–165.
4. Sato T, Emi K, Ikeda T, et al. Severe intraocular inflammation after intravitreal injection of bevacizumab. *Ophthalmology*. 2010;117(3):512–513.
5. Wickremasinghe SS, Michalova K, Gilhotra J, et al. Acute intraocular inflammation after intravitreal injections of bevacizumab for treatment of neovascular age related macular degeneration. *Ophthalmology*. 2008;115(11):1911–1915.

Clinical Ophthalmology

Publish your work in this journal

Clinical Ophthalmology is an international, peer-reviewed journal covering all subspecialties within ophthalmology. Key topics include: Optometry; Visual science; Pharmacology and drug therapy in eye diseases; Basic Sciences; Primary and Secondary eye care; Patient Safety and Quality of Care Improvements. This journal is indexed on

Submit your manuscript here: <http://www.dovepress.com/clinical-ophthalmology-journal>

Dovepress

PubMed Central and CAS, and is the official journal of The Society of Clinical Ophthalmology (SCO). The manuscript management system is completely online and includes a very quick and fair peer-review system, which is all easy to use. Visit <http://www.dovepress.com/testimonials.php> to read real quotes from published authors.